

**RE# MJVR - 0017-2015****SPLENIC ABSCESS IN A GERMAN SHEPHERD DOG****MADHAVAN UNNY N.\*, MANJU GEORGE, AJITH J. GEORGE AND USHA N. PILLAI**

Department of Clinical Veterinary Medicine, College of Veterinary and Animal Sciences, Mannuthy, Thrissur, Kerala, India

\* Corresponding author: madhavanunny@gmail.com

**ABSTRACT.** Splenic abscess is an uncommon condition in dogs. A 10-year-old German Shepherd dog was presented to the small animal medical unit of the University Veterinary Hospital, Mannuthy, with the history of anorexia. Abdominal palpation revealed splenomegaly and on ultrasonography a circumscribed mixed echogenic mass was noticed within splenic parenchyma. Post-mortem examination of the spleen and histopathology of the splenic lesion was consistent with splenic abscess.

*Keywords:* splenic abscess, ultrasonography, histopathology

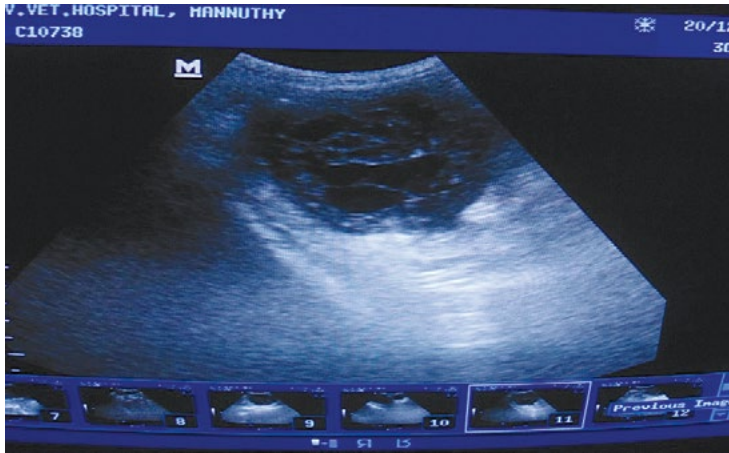**INTRODUCTION**

Splenic abscess represents a rare condition in dogs (Sprangler and Culbertson, 1992; Mahesh and Ranganath, 2009). The clinical presentation of such cases can be variable. Abdominal pain, lethargy, fever and splenomegaly on abdominal palpation have been reported (Volk and Holt, 2010). In dogs and cats, localised splenomegaly can be associated with a variety of conditions including infarcts, nodular hyperplasia, hematoma, abscess and cysts.

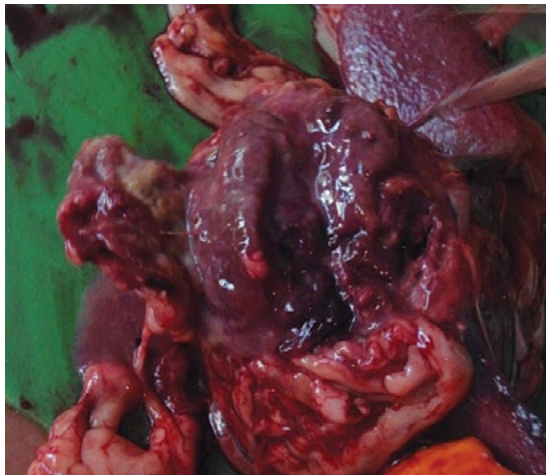
A ten-year-old male German shepherd dog was presented to the small animal medical unit of the University Veterinary Hospital, Mannuthy, with the history of anorexia and weakness for two weeks. As the animal had fever, the animal was treated earlier by a veterinarian with antibacterials for seven days, with no improvement.

The animal was subjected to detailed clinical examination and the body temperature was found to be elevated (105 °F) and mucous membranes were congested. A mild distension of the abdomen was recorded and the animal exhibited pain on abdominal palpation. Splenomegaly could be appreciated on palpation. Blood was collected for complete blood count and peripheral blood smears were prepared for microscopic examination. Ultrasonographic examination of the abdomen was carried out.

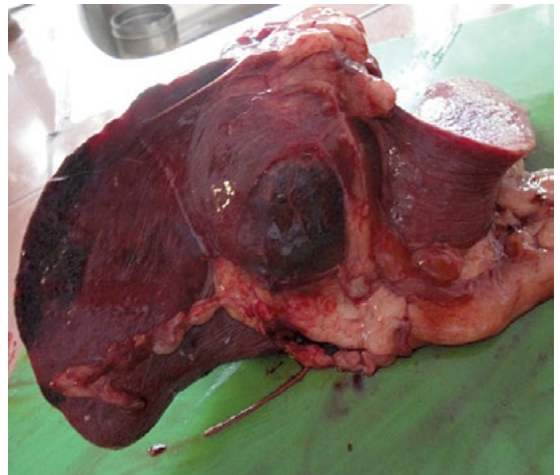Haematology revealed leucocytosis with neutrophilia (87%) and a left shift. Blood smear was negative for haemoprotezoans. Ultrasonographic examination of the abdomen revealed a large circumscribed mass of mixed echogenicity within the normal splenic



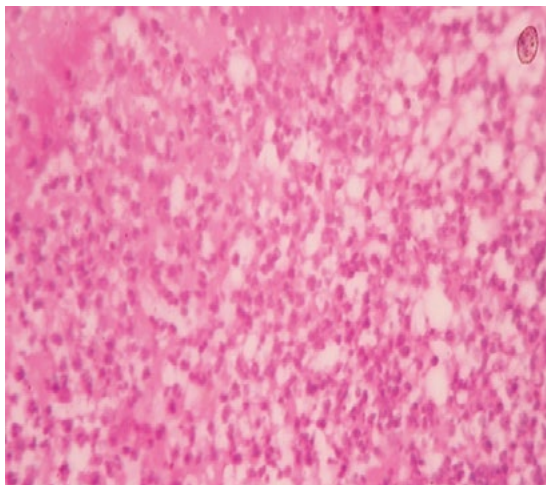
**Figure 1.** Focal circumscribed splenic abscess on ultrasonography



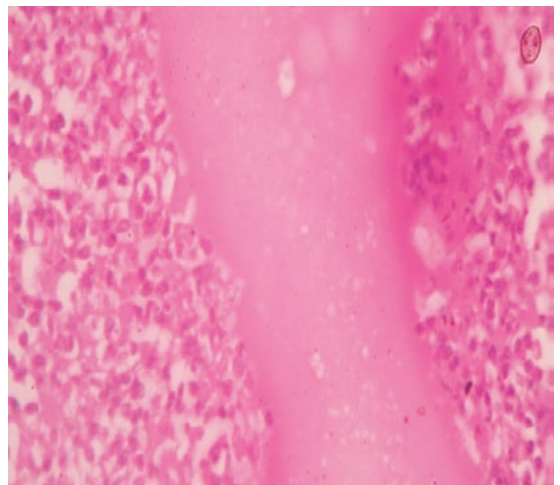
**Figure 2.** Gross lesion within splenic parenchyma



**Figure 3.** Abscess on opening



**Figure 4.** Splenic necrosis



**Figure 5.** Severe neutrophilic infiltration

parenchyma (Figure 1). Hyperechoic areas were noticed within the mass. The case was tentatively diagnosed as splenic abscess based on ultrasonography and haematology findings. The owner was advised of the condition and the need for ultrasound guided aspiration studies and or surgical exploration and aggressive antibacterial management. The owner was not willing to proceed with the treatment and requested that the animal be euthanised. After due consultations with the owner, the animal was euthanised, following standard humane euthanasia procedure and a post-mortem examination was conducted. Post-mortem examination revealed congested abdominal organs. A circumscribed lesion was noticed in the middle of the body of spleen and was soft in consistency (Figure 2). Inflammatory reaction was noticed in splenic capsule. Haemorrhagic areas were noticed within splenic parenchyma. The mass on opening contained pus mixed with blood (Figure 3). Tissue sample was collected for histopathology. Histopathology revealed extensive areas of splenic necrosis (Figure 4) with large number of neutrophils (Figure 5).

The etiology of splenic abscess is considered to be multifactorial. It is suggested that hematogenous spread is a potential cause (Volk and Holt, 2010). Splenic abscess represent either a local or multifocal lesion. Ultrasonography alone may not be beneficial in reaching a diagnosis of splenic abscess as conditions like cyst, nodular hyperplasia, necrosis and

hematoma may result in similar ultrasound findings. It is suggested that a diagnosis of splenic abscess could be reached only based on further diagnostic work, along with ultrasound studies (Nyland and Mattoon, 2015). In the present case, leukocytosis with neutrophilia was suggestive of an abscess. Gross and histopathological studies of the spleen, the results of which were consistent with changes associated with abscess formation (Abdelatiff *et al.*, 2014), was useful in reaching a definitive diagnosis.

## REFERENCES

1. Abdelatiff A., Gunther C., Pepler C and Kramer M. (2014). A rare case of splenic abscess with septic peritonitis in a German shepherd dog. *BMC Vet. Res.* **10**:201. doi: 10.1186/s12917-014-0201-z.
2. Mahesh V and Ranganath L (2009). Splenic abscess in a dog. *Indian J. Vet. Surg.* **30**: 58.
3. Nyland T.G. and Mattoon J.S. (2015). *Small Animal Diagnostic Ultrasound*. Mattoon, J. S and Nyland, T.G. Eds. 3<sup>rd</sup> Edn. Elsevier and Saunders, St. Louis, Missouri. pp 403.
4. Sprangler W.L. and Culbertson M.R. (1992). Prevalence, type and importance of splenic diseases in dogs: 1480 cases (1985-1989). *J. Am. Vet. Med. Assoc.* **200**:829-834.
5. Volk S.W. and Holt D. (2010). *Text Book of Veterinary Internal Medicine*. Ettinger, S. J and Feldman, E. C. Eds. 7<sup>th</sup> Edn. Saunders Elsevier, St. Louis, Missouri. pp 514-515.