

CASE REPORT

A CASE REPORT ON THE 2017 HIGHLY PATHOGENIC AVIAN INFLUENZA (H5N1) OUTBREAK IN POULTRY IN KELANTAN

ZUBAIDAH M.A.*, TARIQ J., NUR RAIHAN M. A., ABD HALIM H.

Regional Veterinary Laboratory Kota Bharu, Kompleks Jabatan Perkhidmatan Veterinar Kubang Kerian, 16150 Kota Bharu, Kelantan

* Corresponding author: zubaidah.mat.amin@gmail.com

ABSTRACT. Highly pathogenic avian influenza (HPAI) is caused by influenza virus A from the family Orthomyxoviridae. It is a severe, systemic disease with high mortality in avians. The mortality can be as high as 100% in a few days. On 28 February 2017, HPAI virus of H5N1 subtype was confirmed in village chickens at Kampung Pulau Tebu, Batu 5, Tunjong Kota Bharu, Kelantan. It was the second outbreak of HPAI in Kelantan after the first reported case at Tumpat Kelantan on 17 August 2004. Most of the dead poultry showed similar clinical signs of sudden death with high mortality, cyanosis and oedema of head, comb, wattle and snood as well as red discolouration of shanks and feet. Post-mortem was performed on dead poultry and there were generalised haemorrhages of all internal organs, congested mesenteric blood vessels and pinpoint haemorrhages on proventriculus. Histopathological examination revealed generalised pulmonary haemorrhages with moderate interstitial pneumonia, generalised hepatic haemorrhages and hepatitis with multifocal area of hepatic necrosis, generalised haemorrhagic myocarditis and generalised haemorrhagic nephritis. Confirmation test was performed

using RT-PCR and viral isolation at Veterinary Research Institute, Ipoh. 36 foci were affected involving five districts (Kota Bharu, Tumpat, Bachok, Pasir Mas and Tanah Merah) causing depopulation of 56,953 poultry and 17,531 eggs. Surveillance and control measures were taken by Department of Veterinary Services to contain the disease from spreading to other areas.

Keywords: avian influenza, poultry, post-mortem, histopathology, surveillance, control measure

INTRODUCTION

HPAI is caused by influenza virus A of the family Orthomyxoviridae (Swayne *et al.*, 2000). The virus are further divided into 16 haemagglutinin (H1-16) and 9 neuraminidase (N1-9) subtypes. Most AI viruses (H1-16 subtypes) are of low pathogenicity, but some of the H5 and H7 AI viruses are highly pathogenic for chickens, turkeys and related gallinaceous domestic poultry. It is a severe systemic disease with high mortality in avians and the mortality can be as high as 100% in a few days (Alexander *et al.*, 2007).

Incubation period is highly variable, ranging from a few days in individual birds

to two weeks in the flock. The transmission are by ingestion, inhalation and contact exposure. Transmission between farms occur when there are breaches in biosecurity practices by movement of infected poultry or contaminated faeces and respiratory secretion on fomites such as equipment, clothing, vehicle *etc.* (Swayne, 2005).

Clinical signs for HPAI were categorised into three which are peracute cases, acute cases and severe cases. For peracute cases, clinical signs and gross lesions may be lacking before death. On survival of the animal, central nervous system involvement such as torticollis, opisthotonus, incoordination, paralysis and drooping wings may occur. For acute cases, there are oedema of the head, comb, wattle and snood (turkey), oedema and red discolouration of the shanks and feet due to subcutaneous ecchymotic haemorrhages, petechial haemorrhages on visceral organ and in muscles as well as blood-tinged oral and nasal discharge. For severe cases the sign is greenish diarrhoea (Swayne, 2005).

CASE HISTORY

The first outbreak of HPAI in Kelantan was on 17 August 2004 which caused depopulation of 18,537 avians. The second outbreak of HPAI was detected on 28 February 2017 at Kampung Pulau Tebu, Batu 5, Tunjong, Kelantan. The case led to an outbreak of HPAI involving the districts of Kota Bharu, Tumpat, Pasir Mas, Bachok and Tanah Merah. There were 36 foci involved which caused depopulation of 56,953 avians and 17,531 eggs.

The first HPAI case on 2017 was reported to private veterinary practices

and the carcasses were sent to the Regional Veterinary Laboratory Kota Bharu (RVLKB) for post-mortem inspection and investigation. They were adult village chicken carcasses from a small backyard farm located at Kampung Pulau Tebu, Tunjong, Kota Bharu with the complaint of sudden death and signs of swollen face, bluish comb and wattles. The population of chicken in the farm is ten and the mortality rate reported was 60%. This led to other outbreaks in different areas and post-mortems was attended by the rapid action team from RVLKB. Most of the dead poultry showed similar clinical signs.

Clinical Signs And Post-Mortem Findings

Upon inspection on the carcasses, there were cyanosis and oedema of head, comb, wattle, red discolouration of the shanks and feet. Post-mortem findings revealed general haemorrhages on all organs, congested mesenteric blood vessel and pinpoint haemorrhage on proventriculus. Samples of lung, trachea, proventriculus, pancreas, intestine and caeca were taken and sent for virus isolation and detection as well as RNA detection by Polymerase chain reaction (PCR). Lung, liver, kidney and spleen also were sent to histopathology to look for any abnormalities on organs. The result were positive for avian influenza H5N1. See Figures 1 to 7.

Histopathological Findings

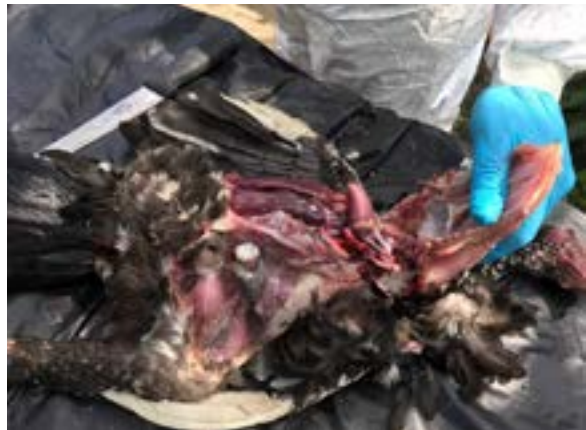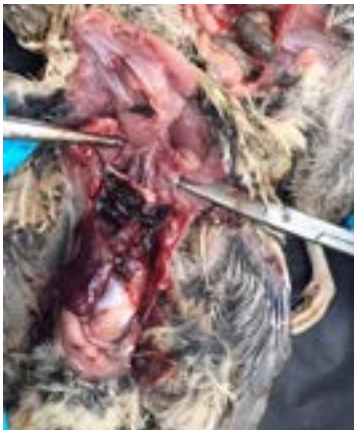Histopathological findings revealed generalised pulmonary haemorrhages with moderate interstitial pneumonia on lung, generalised hepatic haemorrhage and



Figures 1 and 2. Cyanosis and oedema of comb, head and wattles



Figure 3. red discoloration of shanks and feet



Figures 4 and 5. Generalised haemorrhage on all organs

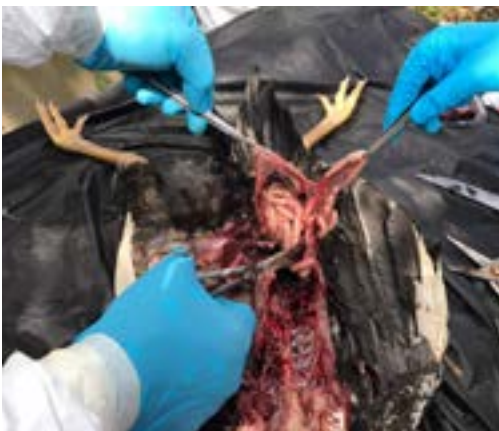

Figure 6. Congested mesenteric blood vessel

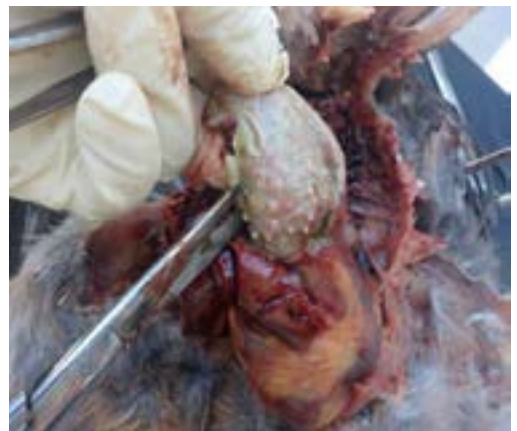

Figure 7. Pinpoint haemorrhage on proventriculus

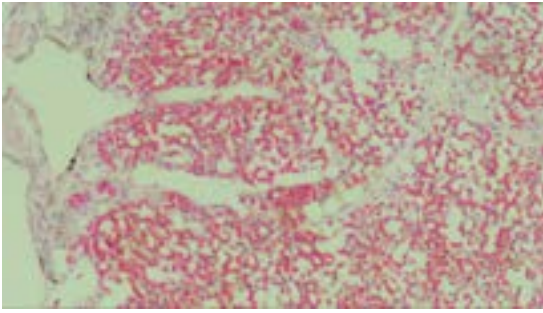


Figure 8. Generalised pulmonary haemorrhages with moderate interstitial pneumonia.

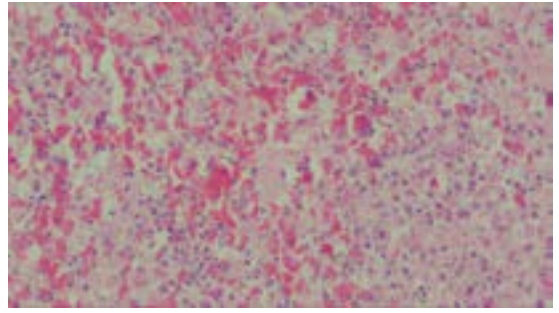


Figure 9. Generalised hepatic haemorrhages and hepatitis with multifocal areas of hepatic necrosis.

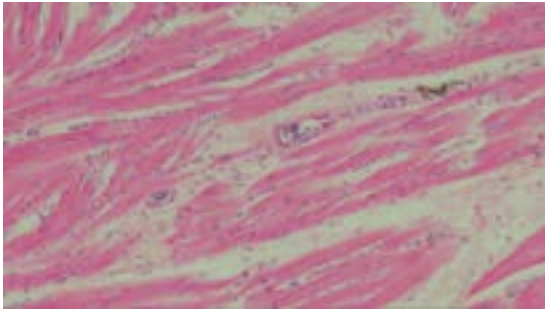


Figure 10. Generalised haemorrhagic myocarditis

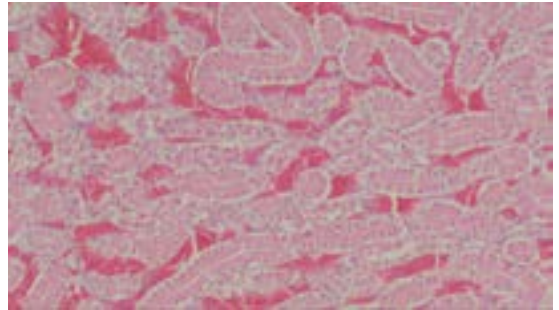


Figure 11. Generalised hemorrhagic nephritis

hepatitis with multifocal areas of hepatic necrosis on liver, generalised haemorrhagic myocarditis on heart and generalised haemorrhagic nephritis in kidney.

DISCUSSION

The case was managed by reporting of the disease according to item 31(1) Akta Binatang 1953 (revision 2006), whereby the poultry are not allowed to be moved out of the premises. Sampling of live and freshly dead poultry was by taking proventriculus, pancreas, intestine, caeca tonsil, trachea and lung from dead poultry while cloacal swab

from live poultry. Confirmatory tests was by PCR and virus isolation.

In the event that the result is negative for AI, the disease quarantine procedure is withdrawn and diagnostic tests for other diseases is carried out. But if the result is positive, confirmation test and zoning of the area into infected and surveillance zones are marked.

An infected zone is the infected premises and its surroundings up to 1 km radius. All poultry and poultry products were culled to ensure that the virus does not spread out of the infected zone. After culling of animals, the premises was then

disinfected and decontaminated. Poultry and poultry products in and out from the infected zone were banned by enforcement teams through road blocks, check points and patrolling activities. The quarantine period was 42 days. All vehicles out from the infected zone were disinfected and poultry rearing was prohibited during the quarantine period.

A surveillance zone is 10 km radius from the infected zone. Surveillance activities on live birds were carried out simultaneously with the culling activities in the infected zone. Movement of poultry and its product out of a surveillance zone were prohibited during this period of surveillance. The quarantine period is 42 days and surveillance were carried out on a scheduled and ongoing basis for 90 days from the date HPAI was last detected. Official notice was on display so that anyone entering the affected premises would have to comply with the proper disinfection procedure.

Vaccination for avian influenza was strictly prohibited unless directed by the Director-General of DVS Malaysia based on the TACB (technical advisory committee on biologics) decision while depopulation was carried out by a stamping out policy.

A few action plans were taken after the outbreak of HPAI, including financial compensation to owners of live poultry suspected of being infected with HPAI and destroyed by Department of Veterinary Services (DVS). The amount of compensation differs according to species. For example, the rate per animal for goose, duck and coloured chicken are RM10, RM6 for broiler duck, RM300 for ostrich, RM5 for partridge, RM9.50 for village chicken, RM4.20 for layer chicken,

RM3 for broiler chicken, RM0.20 for chicken egg and RM0.25 for duck egg. Compensation for exotic birds ranged from RM1 to RM500.

A public awareness campaign on HPAI and the dangers of avian influenza was conducted for poultry farmers, their workers as well as people who were directly involved in poultry rearing. It emphasised on the importance of poultry inspection at a regular basis, reporting of suspicious clinical signs and reporting of sudden death of poultry with high mortality to DVS.

Surveillance in the surveillance zone continued for 3 months after the last HPAI case. Movement of poultry and its products was only permitted when no HPAI disease was detected during surveillance activities. Malaysia submitted application for disease-free recognition from Office International des Epizooties (OIE) when no HPAI disease was detected during the 90-day surveillance.

REFERENCES

1. Swayne D.E. and Suarez D.L. (2000). Highly pathogenic avian influenza. *Revue scientifique et technique-office international des epizooties*, **19(2)**: 463-475.
2. Alexander, D.J. (2007). An overview of the epidemiology of avian influenza. *Vaccine*, **25(30)**: 5637-5644.
3. Swayne D.E. (2005). Avian influenza. Cynthia M. Kahn and Scottline. (eds), *The Merck Veterinary Manual*. 9th Ed. Merck & co., Inc, pp 2297-2298.
4. Jabatan Perkhidmatan Veterinar, (2011). *Protokol Veterinar Malaysia selesema burung (avian influenza)*, Kementerian Pertanian dan Industri Asas Tani Malaysia.