

# SURGICAL MANAGEMENT OF UNILATERAL SEMINOMA IN A DOG

**BINI JOY\*, JOHN MARTIN K.D. AND NARAYANAN M.K.**

Department of Veterinary Surgery and Radiology, College of Veterinary and Animal Sciences, Mannuthy Thrissur, Kerala 680 651

\* Corresponding author: drbinijoy@gmail.com

**ABSTRACT.** Seminomas are one of the common testicular tumours that occur mostly in dogs above five years of age. A case of nine-year-old male German Shepherd dog, presented to University Veterinary Hospital, Kokkalai with a history of swelling on the scrotum for the past two months and its successful surgical management is discussed. The right testicle was found to be highly enlarged and hard while the other atrophied. Histopathological examination following its surgical removal, confirmed it as seminoma.

*Keywords:* seminoma, dog, histopathology

## INTRODUCTION

Seminoma is one of the testicular neoplasia that occurs in dogs. Testicular neoplasia is rare in the bull, ram and boar and, although common in dogs, rarely act as a cause of infertility. Interstitial cell tumours are the most common tumours of the dog. Seminomata, the next most common canine testicular tumour, are also occasionally found in bulls (and stallions), while Sertoli cell tumours are

rarely seen in species other than dogs. Overall, testicular tumours account for over 10% of tumours in male dogs, with a considerably increased incidence in animals with cryptorchid testes (Arthur, 2001). Seminomas are testicular tumours originating from germinal epithelium of seminiferous tubules (Roberts, S. J., 1971). They contribute about 35% of canine testicular tumours and are mostly seen in dogs above five years. Seminomas may become large but are generally innocuous in scrotal testes. They often grow slowly for long periods but may occasionally undergo a sudden increase in the rate of growth. The tumours may become necrotic or haemorrhagic, whereupon affected dogs may exhibit lameness, pain, crouching or hunching. Occasionally, they metastasize to local lymph nodes. Surgical removal of affected testis is indicated in case of seminoma.

## History and Clinical observation

A nine-year-old male German Shepherd dog weighing 30 kg, was presented to the University Veterinary Hospital, Kokkalai with a history of swelling on its scrotum

for the past two months. The animal had been treated with antibiotics for the same and no improvement was noticed. On examination, generalised swelling over the scrotal sac was noticed. Erythematous lesions and pigmentation were noticed all over the scrotal skin. On palpation, the right testicle was found greatly enlarged, about three times than normal, with the surfaces smooth. The other testicle was smaller than usual and was atrophied. Surgical removal of testicles was decided.

### **Treatment and discussion**

The dog was premedicated with intramuscular injections of atropine sulphate (Atrawok, 0.6 mg/ml, Wockhardt Ltd) at the rate of 0.045 mg/kg body weight, followed by xylazine hydrochloride (Xylaxin, 23.22 mg/ml, Indian Immunologicals Ltd) at the rate of 1.5 mg/kg bodyweight at 15 min interval. Anesthesia was induced with ketamine hydrochloride (Aneket, 50 mg/ml, Neon Laboratories Ltd.) given at a rate of 5 mg/kg bodyweight intramuscularly. Anesthesia was maintained with Helibron mixture and diazepam (Calmpose, 5 mg/ml, Ranbaxy Diagnostic Ltd) intravenously to effect.

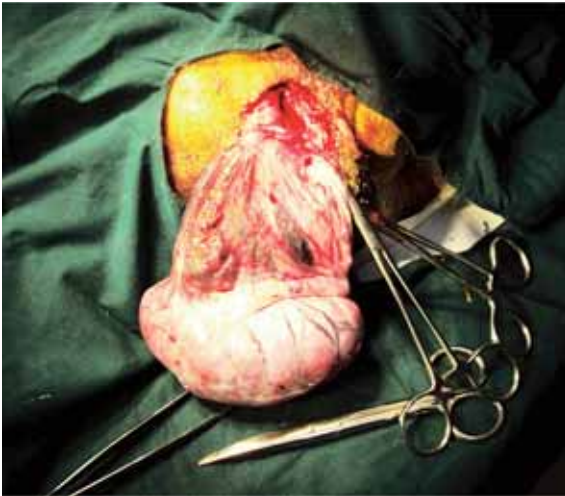### **Surgical procedure**

The animal was controlled in dorsal recumbency. The enlarged testis was held tensed against the dorsal scrotal skin. A single bold incision parallel to the median raphe, cutting through the skin, dartos

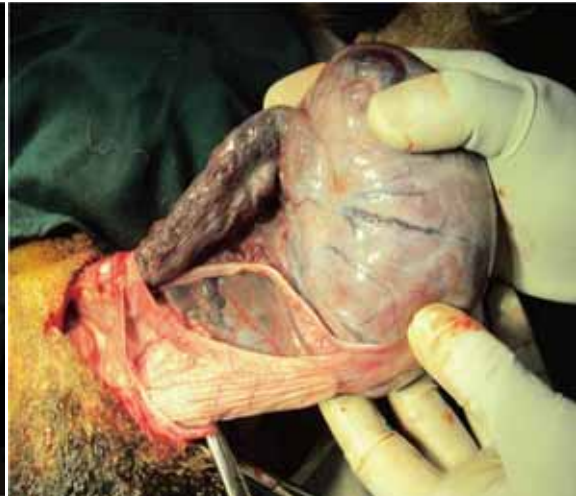and tunica vaginalis was made and the testis was exposed. The scrotal vessels were found highly enlarged. The least vascular part of the spermatic cord was separated. The vessels were clamped and ligated using polyglactin No. 1 (Vicryl, polyglactin 910 suture, Ethicon Inc) and the spermatic cord was severed and removed from the testicle (Figures 1 and 2). Through the same scrotal incision, the other testis which was atrophied was also removed by incising the median scrotal septum (Figure 3). Since the scrotum sac was highly pendulous and with ischemic changes, scrotal ablation was performed after orchietomy (Figure 4). Curvilinear incisions were made on both sides of scrotum at its base, dissected deep and transected. Hemorrhage was controlled by ligation. The subcutis was sutured using polyglactin No. 1 in continuous lockstitch pattern. Skin suture was applied using Nylon in horizontal mattress pattern. Tincture benzoin seal was applied over the suture line.

Post-operatively the dog was treated with ceftriaxone (Intacef, 500 mg injection, Intas Pharmaceuticals Ltd) at a rate of 25 mg/kg bodyweight and meloxicam (Melonex BP, 5 mg, Intas Pharmaceuticals Ltd) at the rate of 0.2 mg/kg bodyweight, both intravenously for five days. Skin sutures were removed on the seventh postoperative day. The dog had an uneventful recovery.

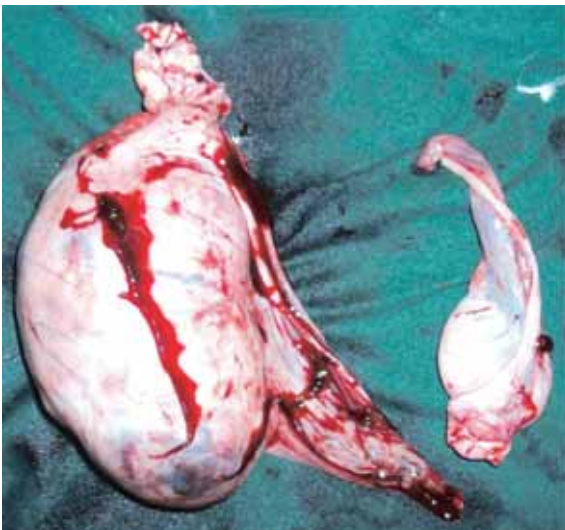
The histopathology of the cut section of the enlarged testis revealed the testicular



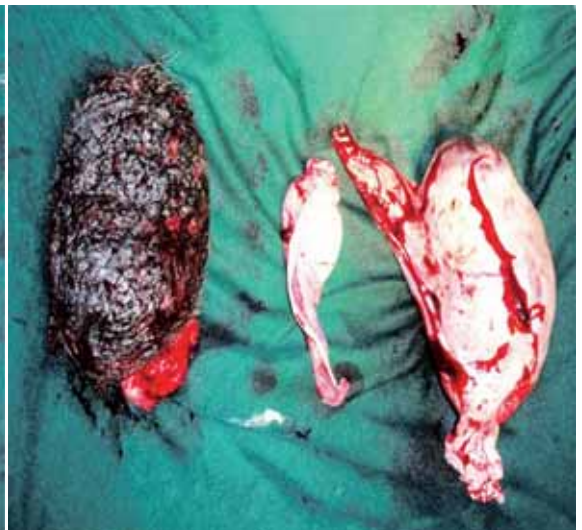**Figure 1**



**Figure 2**



**Figure 3**



**Figure 4**

tumour – seminoma (Figure 4 and Figure 5).

## **DISCUSSION**

Testicular tumors have been reported to have a higher incidence in older dogs

(Mitchell, R., 2002), and it is the second most commonly seen tumours in male dogs. Among the three testicular tumours, *viz.*, interstitial cell tumour, seminoma and sertoli cell tumour, seminomas are second common in incidence. Seminomas arise from the germinal epithelium of

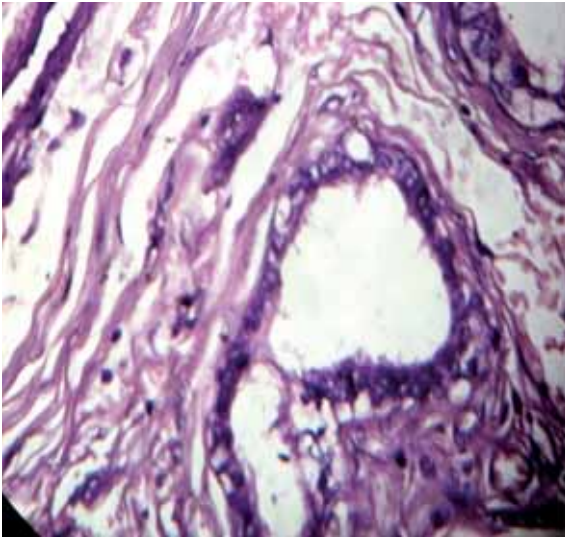


Figure 5

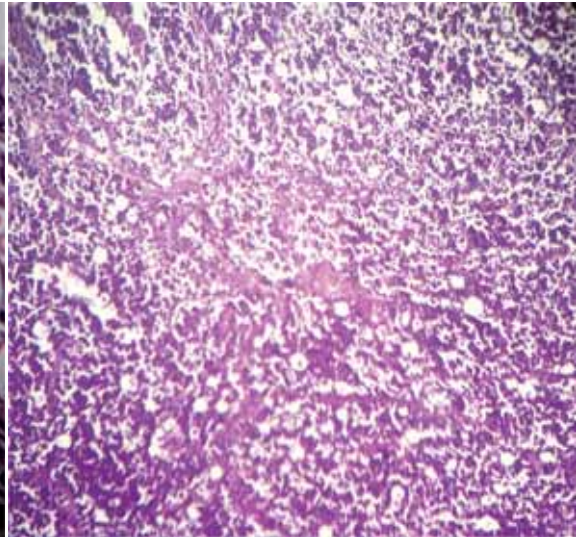


Figure 6

seminiferous tubules and are typically benign tumours, with a metastatic rate of 5-10%. When functional, seminomas produce more amounts of androgen, a prostatic enlargement and perianal adenomas are likely to occur. Clinical signs include increased firmness, generalised enlargement of testis and scrotum, swelling of one or both testes and pain. Signs of feminization like hyperpigmentation are also reported (Grieco *et al.*, 2008). The definitive diagnosis of testicular cell tumours can be reached by an excisional wedge biopsy of the testis away from the epididymis. In the present case, histopathology of the excised testicle revealed the presence of proliferating cells arising from tubular epithelium (Figure 5) and hyperchromatic vesicular nuclei with scarce cytoplasm.

Individual necrotic cells were found in the proliferating sheets of cells, which had a typical star sky pattern (Figure 6), suggestive of benign seminomas. Neoplastic cells were round to polyhedral in shape with distinct cell borders and mild to marked basophilic cytoplasm. Areas of neutrophilic infiltration were also evident. Marked anisocytosis and anisokaryosis with prevalent karyomegalic cells were noticed (Masand *et al.*, 2013). For the vast majority of testicular tumours, orchiectomy is suggested as the treatment (Dhaliwal *et al.*, 1999).

## SUMMARY

Seminomas are the second most common testicular tumours in dogs above five years. In this report, the case of a nine-

year-old male German shepherd dog with the clinical signs of generalised swelling of the scrotum for the past two months, unilateral enlargement of right testis and atrophy of left testis is presented. The dog was subjected to bilateral orchiectomy and scrotal ablation under general anesthesia. Histopathology of the enlarged testis confirmed it as a case of seminoma.

## REFERENCES

1. Mitchell, R. 2000. Reproductive oncology In: Slatter, D. H. ed. *Text Book of Small Animal Surgery*. 3<sup>rd</sup> Edn. Saunders Company, Philadelphia. pp. 2443
2. Arthur, G. H. 2001. *Arthur's Veterinary Reproduction and Obstetrics*, 8<sup>th</sup> ed. Saunders Company. Elsevier Ltd. pp.735
3. Dhaliwal, R.S., Kithcell, B.E. Knight, B.L. and Schmidt B. R. 1999. Treatment of aggressive testicular tumors in four dogs. *J. Am. Anim. Hosp. Assoc.* 35: 311-318
4. Grieco, V., Riccardi, E. and Greppi, G.F. 2008. Canine testicular tumours - A study on 232 dogs. *J. Comp. Path.* 138: 86-89
5. Roberts, S.J., 2004. *Veterinary Obstetrics and Genital Diseases*. 2nd Ed. CBS Publisher. pp.776.
6. Masand, A., Kumar, N., Patial, V. 2013. Unilateral diffuse spermatocytic seminoma in a dog. *Vet. Res. International*. October-December.1: 46-48
7. Takiguchi, M., Iida, T., Kudo, T., and Hashimoto, A.. 2001. Malignant seminoma with systemic metastases in a dog. *J. of Sm. Anim. Pract.* 42:7: 360-362.