

THE DIAGNOSIS OF *BLASTOCYSTIS* SP. FROM ANIMALS — AN EMERGING ZONOSIS

HEMALATHA C.^{2*}, CHANDRAWATHANI P.¹, SURESH KUMAR G.², PREMAALATHA B.¹, GEETHAMALAR S.¹, LILY ROZITA M.H.¹, FARAH HAZIQAH M.T.², SABAPATHY D.³ AND RAMLAN M.¹

1 Veterinary Research Institute 59, Jalan Sultan Azlan Shah, 31400, Ipoh, Perak, Malaysia

2 Department of Parasitology, Faculty of Medicine, University of Malaya, 50603 Kuala Lumpur, Malaysia.

3 Bukit Merah Laketown Resort Ecopark, Jalan Bukit Merah, 34400 Semangol, Perak, Malaysia

* Corresponding author: hemaum25@gmail.com

ABSTRACT. A total of 302 faecal specimens from animals of various species including poultry, ruminants, mammals, swine, primates, companion animals, wild animals, and laboratory animals were examined for the presence of *Blastocystis* sp. These anaerobic parasites which are environmentally resistant were found in 104 specimens (34.44%), that is, from ostriches, pigs, ruminants and non-human primates whereas samples from other animals were completely free of the organism. There is a need to assess the impact of these infections on the productivity of animals and its importance in human infections.

Keywords: *Blastocystis* sp., morphology, zoonotic, *in vitro* culture

INTRODUCTION

Blastocystis sp. is an anaerobic enteric protozoan organism of the intestinal tract of a range of animals, including humans which can be symptomatic or asymptomatic (Boreham and Stenzel, 1993). *Blastocystis* sp. is a polymorphic organism and the four

common forms are the vacuolar, granular, amoeboid and cysts forms (Stenzel and Boreham, 1996). Among all the forms, the fecal cyst is the only environmentally resistant transmissible form (Leelayoova *et al.*, 2002).

It is generally assumed that *Blastocystis* sp. is transmitted by fecal-oral route in a manner similar to other gastrointestinal protozoan but this has not been confirmed experimentally (Nimri *et al.*, 1994; Lambert M. *et al.*, 1992). On the other hand, the clinical signs and symptoms of *Blastocystis* sp. are non-specific and associated with gastrointestinal symptoms such as diarrhoea, abdominal pain, vomiting, anorexia and flatulence. However, more pathogenic symptoms such as intestinal inflammation, altered bowel habits, lethargy, chronic diarrhea and death were observed in animals with severe infection (Boreham and Stenzel, 1993; Stenzel and Boreham, 1996; Tan *et al.*, 2002).

Based on the previous publications, *Blastocystis hominis*-like organisms have been detected in a wide range of

animals including non-human primates, mammalian, avian, amphibians and reptilian hosts and less frequently in rats, reptiles and insects (Yamada *et al.*, 1987; Teow *et al.*, 1991; Zaman *et al.*, 1993; Quilez *et al.*, 1995a, 1995b; Stenzel and Boreham, 1996; Konig and Muller, 1997; Chen *et al.*, 1997a; Yoshikawa *et al.*, 1998a; Belova and Krylov, 1998; Lee and Stenzel, 1999; Abe *et al.*, 2002 and Yoshikawa *et al.*, 2004b). Many publications have highlighted the high prevalence of *Blastocystis* sp. in various animal hosts (Abe *et al.*, 2002; Tan *et al.*, 2004; Noel *et al.*, 2005; Stensvold *et al.*, 2009 and Parkar *et al.*, 2010). In Malaysia, (Lim Y.A.L. *et al.*, 2008) have reported on the low occurrence of *Blastocystis* sp. among the animals at a zoo however, *Blastocystis* infection was reported in five different farms in Peninsular Malaysia with 73 (30.9%) of 236 goats examined were positive for *Blastocystis* sp. recently (Tan *et al.*, 2013).

According to (Doyle *et al.*, 1990), patients who come into close contact with pets or farm animals are more prone to this infection which suggests the possibility of human-animal cross-infectivity. Furthermore, experimental cross-transmission has been achieved in chickens with *Blastocystis* sp. from domestic chickens, quails and domestic geese and in guinea pigs (Phillips *et al.*, 1976) and rats (Suresh *et al.*, 1995) with *Blastocystis* sp. from humans which indicates that *Blastocystis* sp. exhibits low host specificity.

To date, very limited studies have been conducted on the prevalence of *Blastocystis* infection among various animal hosts in Malaysia. Therefore, this study attempts to determine the occurrence of *Blastocystis* infection among domestic, pet and zoo animals which could be a reservoir for human infection when in close association. The present study is the first report on the presence of *Blastocystis* infection among various animal species in Perak.

MATERIALS AND METHODS

Study animals

A total of three hundred and two (n=302) faecal samples of different animal species were collected from various government and private establishments which are located in Perak state commencing from January 2012 to October 2012. The study animals consist of avian, ruminants, mammals, swine, primates, companion animals, wild animals, and laboratory animals. All samples were registered as Veterinary Research Institute specimens for routine diagnosis as they were submitted by parasitology veterinary staffs from state DVS, farmers and collected for screening by laboratory staffs.

Sample collection

For avian, ruminants, mammals, swine, primates, wild animals and laboratory animals, sampling feces off the ground was

conducted whereas samples from smaller ruminant animals such as goats and sheeps were collected per rectum of animal. However, rectal swabs were used for sampling companion animals such as dogs and cats which contain a smaller amount of feces. The fresh fecal samples were stored in stool collection container and were processed as soon after collection.

Screening for *Blastocystis* sp.

Fecal samples were collected and examined for *Blastocystis* sp. by wet preparation under light microscopy. Every specimen were then cultivated for *Blastocystis* sp. using Jones' medium supplemented with 10% heat-inactivated horse serum and incubated at 37°C. (Suresh *et al.*, 1997). Subsequently after isolation, the parasites were maintained in Jones' medium by consecutive subcultures every 2 to 3 days.

RESULTS

Prevalence of *Blastocystis* sp. in animals

As shown in Table 1, a total of 104 out of 302 animals (34.44%) were found positive for *Blastocystis* sp. from fecal examination. High prevalence of Blastocystis infection were observed in the ruminant livestock group; that is 34.5% (10/29) in cattle, 28.6% (4/14) in deers, 30% (3/10) in gaur, 65% (13/20) in goats and 57.9% (22/38) in sheeps. In contrast, all the dogs and cats from the animal clinic were negative for

Blastocystis infection. Meanwhile, avian host such as ostriches were 100% (37/37) positive for *Blastocystis* sp. All wildlife specimens including black panther, lion, tiger, elephants, tapir, camel, terrapins and wild birds were completely free from the organism.

In mammals, the prevalence rate of the organism varied, 50% (5/10) of orang utan and 100% (10/10) of pigs were positive for *Blastocystis* sp., while in horses and chimpanzee, the organism was undetectable. Additionally, specimens from the laboratory animals such as mice, rats, guinea pigs and rabbits were found to be negative.

Light microscopic observation

After subsequent subculturing, the vacuolar forms were predominant in the cultures of all the animal isolate. The size of the forms varied from 15-30 µm in diameter. The range in size of the vacuolar forms did not differ among isolates from different animal hosts. Granular and amoeboid forms were rarely seen in the cultures. The average size range of granular forms was 5 to 50 µm in diameter. Binary fission was frequently observed in the cultures.

DISCUSSION

Many epidemiological studies on other intestinal parasites have been conducted in a variety of animals but only two reports on Blastocystis infection involving domestic animals such as goats, gaur,

Table 1: Prevalence of *Blastocystis* sp. in various animal hosts

Types of animals (<i>Scientific names</i>)	Numbers detected positive/examined	Percentage detected positive (%)
Black Panther (<i>Panthera onca</i>)	0/1	0
Camel (<i>Camelus camelopardalis</i>)	0/1	0
Cat (<i>Felis catus</i>)	0/24	0
Cattle (<i>Bos taurus</i>)	10/29	34.5
Chimpanzee (<i>Pan troglodytes</i>)	0/1	0
Deer (<i>Rusa unicolor</i>)	4/14	28.6
Dog (<i>Canis lupus</i>)	0/32	0
Elephant (<i>Elephas maximus</i>)	0/2	0
Gaur (<i>Bos gaurus hubbacki</i>)	3/10	30.0
Goat (<i>Capra aegagrus</i>)	13/20	65.0
Horse (<i>Equus ferus</i>)	0/5	0
Laboratory animal	0/32	0
Lion (<i>Panthera leo</i>)	0/1	0
Orang utan (<i>Pongo pygmaeus</i>)	5/10	50.0
Ostrich (<i>Struthio camelus</i>)	37/37	100.0
Pig (<i>Sus domesticus</i>)	10/10	100.0
Sheep (<i>Ovis aries</i>)	22/38	57.9
Tapir (<i>Tapirus indicus</i>)	0/1	0
Tiger (<i>Panthera tigris</i>)	0/1	0
Terrapin (<i>Batagur borneoensis</i>)	0/3	0
Wild bird	0/30	0
Total	104/302	34.44

cattle, and deer have been completed in Malaysia (Lim Y.A.L *et al.*, 2008 and Tan *et al.*, 2013). In the present study, moderate infection were observed in the ruminant live stock group which includes cattle (34.5%), deer (28.6%), gaurs (30%), goats (65%) and sheeps (57.9%) which was similar to the European countries (Quilez *et al.*, 1995a and Pakandl., 1991) and Japan (Abe *et al.*, 2002).

In our study, high prevalence was observed in the ostriches (100%) and pigs (100%) which were consistent with the studies in ostriches using samples from Spain (Ponce G.F. *et al.*, 2002) and pigs from Japan (Abe *et al.*, 2002). High infection in these animals might be due to housing condition where ostriches are reared in an open space pens which are easily exposed to birds and pigs are housed together or caged close to other animals.

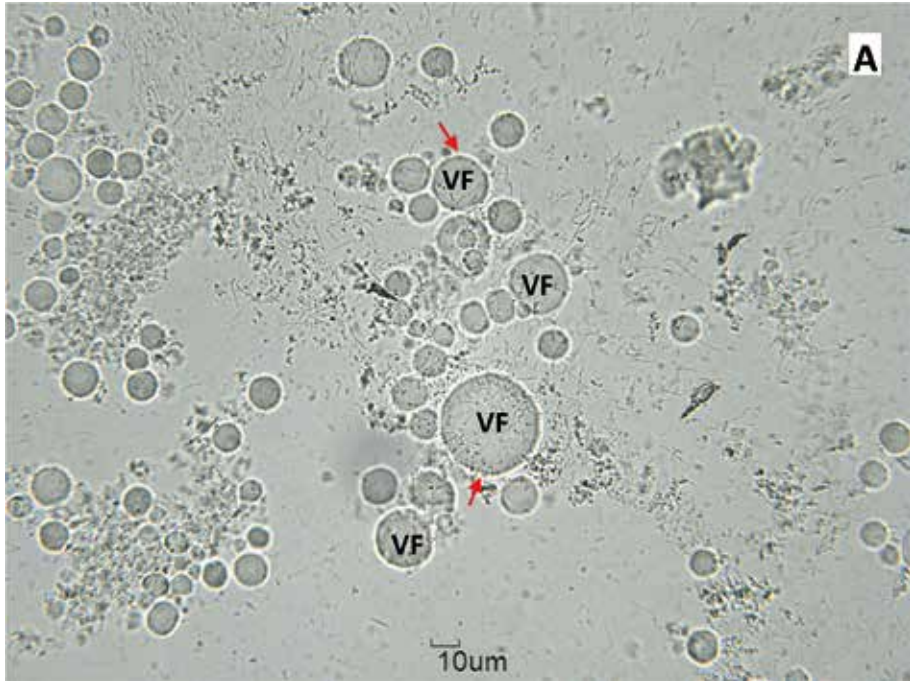


Figure 1A. Light microscopical images of *Blastocystis* sp. from fecal culture (40x magnification); VF, vacuolar.

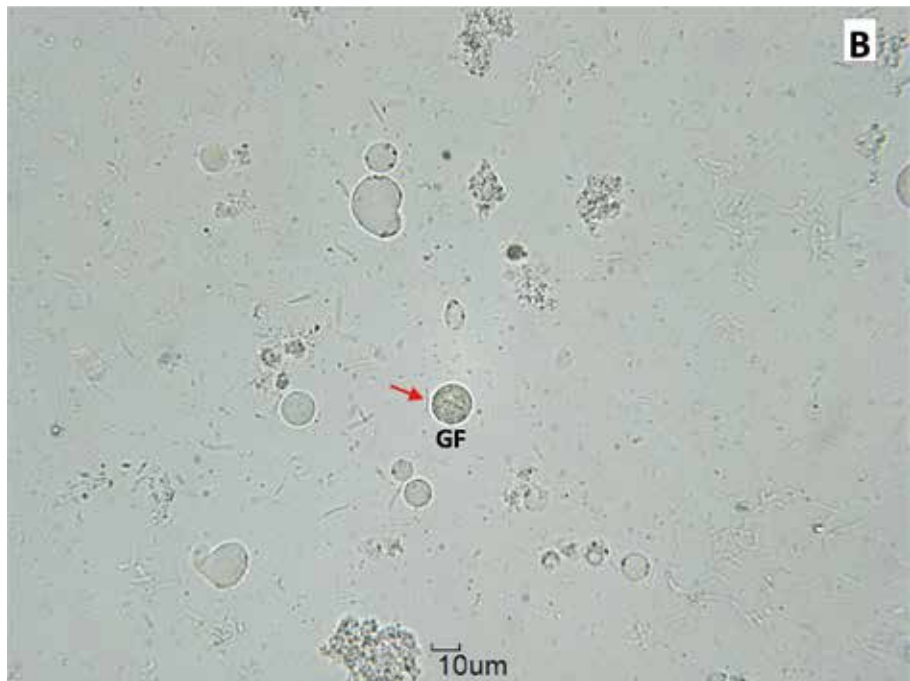


Figure 1B. Light microscopical images of *Blastocystis* sp. from fecal culture (40x magnification); GF, granular form.

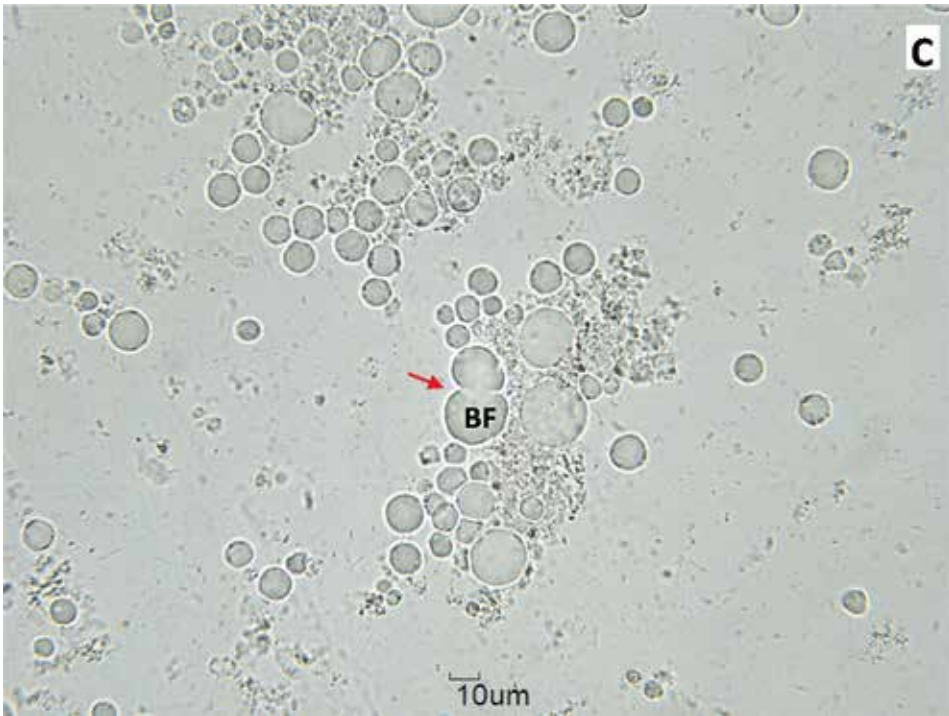


Figure 1C. Light microscopical images of *Blastocystis* sp. from fecal culture (40x magnification); BF, binary fission.

As for the primates, 50% of the orang utan were positive for *Blastocystis* infection, however the chimpanzee was negative. These occurrence are relatively moderate, while it was reported to be high among the primates in Japan with 85% of them were positive for this organism (Abe *et al.*, 2002). It was speculated that *Blastocystis* infection had been transmitted by contact with neighbouring primates since some of the primates are housed together. Meanwhile, the chimpanzee sample obtained from a zoo was negative possibly because the primates in the zoo are housed individually.

In the present study, the absence of this organism in companion animals was similar to the studies in dogs and cats conducted in Germany and Japan (Konig and Muller, 1997; and Abe *et al.*, 2002). The cats and dogs sampled were not strays and had owners. They were kept in as domesticated pets within house premises. Thus this could explain the absence of *Blastocystis* sp. in these animals. In addition, horses and laboratory animals were also negative for *Blastocystis* infection in this study and similar findings were reported in Australia (Roberts T. *et al.*, 2013). However, it has been reported that 60-70% of the laboratory rats were

found to be positive for *Blastocystis* sp. whereas all the mice, rabbits and hamsters were negative (Chen *et al.*, 1997) due to management where rabbits stools drop to the tray meanwhile the rats stay in the same bedding.

All the wildlife specimens in our study including black panther, lion, tiger, elephants, tapir, camel, terrapins and wild birds were completely free from *Blastocystis* infection. These results are consistent with the study conducted in Germany and Japan (Konig and Muller, 1997 and Abe *et al.*, 2002). However, a study conducted among the circus animals in Australia (Stenzel *et al.*, 1993) reported that lion and camel were found to be positive for *Blastocystis* sp. In this study, most of the wildlife animals are housed separately or within their groups which probably reduce the chances of cross-transmission.

CONCLUSION

This study highlighted the importance of monitoring *Blastocystis* infection among domestic, pet and zoo animals which are in close contact with humans and could be a reservoir for human infection. Further molecular studies need to be conducted in order to have a better understanding on the reservoir hosts and origin of *Blastocystis* infection among animals. As *Blastocystis* infection is fast becoming a common feature in humans, there is a need to screen animals and maintain good hygiene during processing of meat and meat products to

eliminate the risk of infection to humans. The present study warrants that animal handlers need to be educated on personal hygiene, such as wearing of a mask and gloves to eliminate the risk of *Blastocystis* infection to humans.

REFERENCES

1. Abe N., Nagoshi M., Takami K., Sawano Y. and Yoshikawa H. (2002): A survey of *Blastocystis* sp. in livestock, pets, and zoo animals in Japan. *Veterinary Parasitology*, **106**: 203-212.
2. Belova L.M. and M.V. Krylov. (1998): The distribution of *Blastocystis* according to different systematic groups of hosts. *Parazitologiya*, **32(3)**: 268.
3. Boreham P.F.L. and Stenzel D.J. (1993): *Blastocystis* in humans and animals morphology, biology, and epizootiology, *Advance Parasitology*, **32**: 1-70.
4. Chen X.Q., Singh M., Ho L.C., Tan S.W., Ng G.C., Moe K.T. and Yap E.H. (1997): Description of a *Blastocystis* species from *Rattus norvegicus*. *Parasitology Research*, **83 (4)**: 313-318.
5. Doyle P.W., Helgaso, M.M., Mathias R.G. and Proctor E.M. (1990): Epidemiology and pathogenicity of *Blastocystis hominis*. *Journal of Clinical Microbiology*, **28(1)**: 116-121.
6. Konig G. and Muller H.E. (1997): *Blastocystis hominis* in animals: incidence of four serogroups. *Zentralbl Bakteriol*, **286**: 435-440.
7. Lambert M., Gigi J. and Bughin C. (1992): Persistent diarrhoea and *Blastocystis hominis*. *Acta Clinica Belgica*, **47(2)**: 129.
8. Lee M.G. and Stenzel, D.J. (1999): A survey of *Blastocystis* in domestic chickens. *Parasitology Research*, **85**: 109-117.
9. Leelayoova S., Taamasri P., Rangsin R., Naaglor T., Thathaisong U. and Mungthin M. (2002): In-vitro cultivation: a sensitive method for detecting *Blastocystis hominis*. *Annals of Tropical Medicine and Parasitology*, **96(8)**: 803-807.
10. Lim Y.A.L., Ngui R., Shukri J., Rohela M. and Mat Naim H.R. (2008): Intestinal parasites in various animals at a zoo in Malaysia. *Veterinary Parasitology*, **157(1)**: 154-159.
11. Nimri., Laila and Raymond B. (1994): Intestinal colonization of symptomatic and asymptomatic schoolchildren with *Blastocystis hominis*. *Journal of Clinical Microbiology*, **32(11)**: 2865-2866.

12. Noel C., Dufernez F., Gerbod D., Edgcomb V.P., Delgado V.P., Ho L.C. and Viscogliosi E. (2005): Molecular phylogenies of *Blastocystis* isolates from different hosts: implications for genetic diversity, identification of species, and zoonosis. *Journal of Clinical Microbiology*, **43(1)**: 348-355.
13. Pakandl, M. (1991): Occurrence of *Blastocystis* sp. in pigs. *Folia Parasitologica*, **38(4)**: 297.
14. Parkar U., Traub R.J., Vitali S., Elliot A., Levecke B., Robertson I., Geurden T., Steele J., Drake B. and Thompson R.C. (2010): Molecular characterization of *Blastocystis* isolates from zoo animals and their animal keepers. *Veterinary Parasitology*, **169(1)**: 8-17.
15. Phillips B.P. and Zierdt C. H. (1976): *Blastocystis hominis*: Pathogenic potential in human patients and in gnotobiotics. *Experimental Parasitology*, **39(3)**: 358-364.
16. Ponce Gordo F., Herrera S., Castro A.T., Garcia Duran B. and Martinez Diaz R.A. (2002): Parasites from farmed ostriches (*Struthio camelus*) and rheas (*Rhea americana*) in Europe. *Veterinary Parasitology*, **107(1)**: 137-160.
17. Quilez J., Clavel A., Sanchez-Acedo C. and Causape A.C. (1995a): Detection of *Blastocystis* sp. in pigs in Aragon (Spain). *Veterinary Parasitology*, **56**: 345-348.
18. Quilez J., Sanchez-Acedo C., Clavel A. and Causape A.C. (1995b): Occurrence of *Blastocystis* sp. in cattle in Aragon, northeastern Spain. *Parasitology Research*, **81**: 703-705.
19. Roberts T., Stark D., Harkness J. and Ellis J. (2013): Subtype distribution of *Blastocystis* isolates from a variety of animals from New South Wales, Australia. *Veterinary Parasitology*, **196(1)**: 85-89.
20. Stensvold C.R., Alfellani M.A., Norskov-Lauritsen S., Prip K., Victory E.L., Maddox C. and Clark C.G. (2009): Subtype distribution of *Blastocystis* isolates from synanthropic and zoo animals and identification of a new subtype. *International Journal for Parasitology*, **39(4)**: 473-479.
21. Stenzel D.J., Cassidy M.F. and Boreham P. F. L. (1993): Morphology of *Blastocystis* sp. isolated from circus animals. *International Journal for Parasitology*, **23(5)**: 685-687.
22. Stenzel D.J. and Boreham P.F.L. (1996): *Blastocystis hominis* revisited. *Clinical Microbiology Reviews*, **9**: 563-584.
23. Suresh K., Chong S.Y., Howe J., Ho L.C., Ng G.C., Yap E.H. and Singh M. (1995): Tubulovesicular elements in *Blastocystis hominis* from the caecum of experimentally infected rats. *International Journal for Parasitology*, **25(1)**: 123-126.
24. Suresh K., Khairul Anuar A., Saminathan R., Ng K.P. and Init I. (1997): *In vitro* culture technique: a better diagnostic tool for *Blastocystis hominis*. *International Medical Research Journal*, **1**: 5-7.
25. Tan K.S.W., Singh M. and Yap E.H. (2002): Recent advances in *Blastocystis hominis* research: hot spots in terra incognita. *International Journal for Parasitology*, **32**: 789-804.
26. Tan K.S. (2004): *Blastocystis* in humans and animals: new insights using modern methodologies. *Veterinary Parasitology*, **126(1)**: 121-144.
27. Tan T. C., Tan P. C., Sharma R., Sugnaseelan S. and Suresh K.G. (2013): Genetic diversity of caprine *Blastocystis* from Peninsular Malaysia. *Parasitology Research*, **112(1)**: 85-89.
28. Teow W L., Zaman V., Ng G.C., Chan Y.C., Yap E.H., Howe J., Gopalakrishnakone P. and Singh M. (1991): A *Blastocystis* species from the sea-snake, *Lapemis hardwickii* (Serpentes, Hydrophiidae). *International Journal for Parasitology*, **21**: 723-726.
29. Yamada M., Yoshikawa H., Tegoshi T., Matsumoto Y., Yoshikawa T., Shiota T. and Yoshida Y. (1987): Light microscopical study of *Blastocystis* spp. in monkeys and fowls. *Parasitology Research*, **73**: 527-531.
30. Yoshikawa H., Morimoto K. and Nagashima M. (1998a): Isolation and characterization of *Blastocystis* spp. isolated from anuran amphibians. Ninth International Congress of Parasitology 1988. *International Proceedings Division, Bologna*, pp: 1075-1079.
31. Yoshikawa H., Niichiro A. and Zhiliang W. (2004): PCR-based identification of zoonotic isolates of *Blastocystis* from mammals and birds. *Microbiology* **150 (5)**: 1147-1151.
32. Zaman V., Ng G.C., Suresh K., Yap E.H. and Singh M. (1993): Isolation of *Blastocystis* from the cockroach (Dictyoptera: Blattidae). *Parasitology Research*, **79**: 73-74.

ACKNOWLEDGEMENT. The authors would like to thank University Malaya and PPP Research Grant PV133-2012A for supporting this study. A special thanks to all the staffs of the Parasitology and Haematology section at the Veterinary Research Institute Ipoh for their help in collecting samples for this study and also to all the staffs of the government and private establishments involved in this study for their support and cooperation.